

Enhanced gingival esthetics for natural looking complete dentures

Optimizing conventional complete dentures with an innovative veneering material
Dr Jiro Abe, Tokyo/Japan

Stability, function and esthetics: when fabricating complete dentures, optimum results can only be achieved if the individual details are successfully combined. In addition to the rehabilitation of functional aspects, the esthetic reconstruction of the teeth and soft oral tissues can considerably enhance a patient's self-confidence.

Treating edentulous patients using conventional complete dentures continues to be a frequently applied therapy option. Yet, populating the edentulous jaw with denture teeth to achieve a functional and esthetic rehabilitation poses a tough challenge to the treatment team. Biomechanical, physiological and geriatric concerns must be considered. True-to-nature replication of teeth and soft oral tissues also plays a key part. The objective is to give patients some of their personality back by providing them with natural looking dentures.

Initial situation

Aged 58, this relatively young female patient presented with an edentulous upper jaw. She was wearing a complete denture in the maxillary arch and inadequate metal-ceramic restorations in the mandibular arch. Her existing teeth were damaged and could not be used as abutments for new restorations. They had to be extracted. The patient was diagnosed with Angle Class III malocclusion. There was a severe anteroposterior discrepancy between the upper and lower arch. Seen in profile, the patient showed a prominently jutting chin and a protruding lower lip (Fig. 1). Her esthetic appearance was impaired. In addition, the patient complained about the

poor function and high mobility of the maxillary denture. A flabby ridge and severe bone resorption were present in the anterior part of the maxilla (Fig. 2). The alveolar ridge showed an asymmetrical progression in the mandibular arch (Fig. 3). Following the initial assessment of the patient's oral conditions and consultation on the treatment options available to her, we decided to create new dentures for the maxillary and mandibular jaw. Conventional complete dentures were selected as the treatment option.

Model analysis

We began by taking a closed-mouth impression to create a primary record of the jaw relations. Accurate model analysis provided important information in preparation for the individual functional impression. These steps established the basis for a statically and functionally correct design of the dentures. The median palatine raphe, incisive papilla, first large palatine rugae, tuber maxillae and crest of the alveolar ridge were marked on the maxillary model. On the mandibular model, the crest of the alveolar ridge, Pound's line and the Tuberculum alveolare mandibulae were marked as landmarks. The mucobuccal fold was determined on both models.

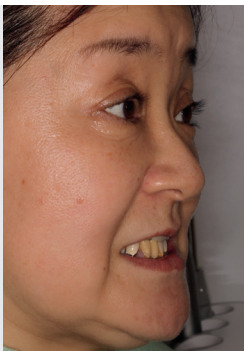

Fig. 1: Profile picture of the initial situation (Angle Class III)

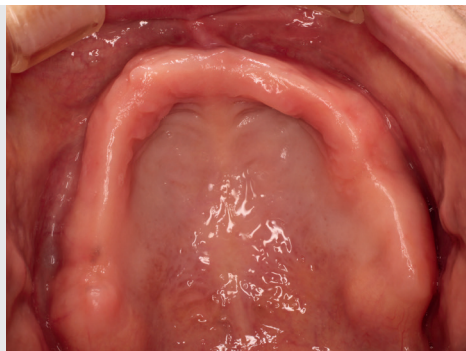


Fig. 2: Edentulous upper jaw with a flabby ridge in the anterior region and advanced bone resorption

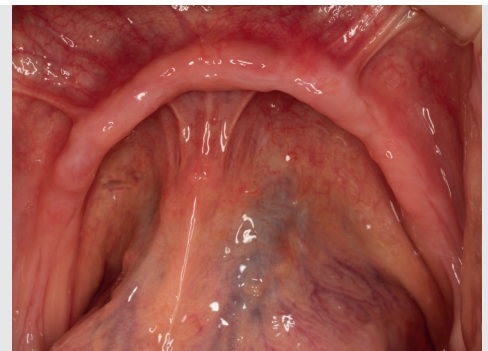

Fig. 3: Asymmetrical alveolar ridge progression in the mandibular arch

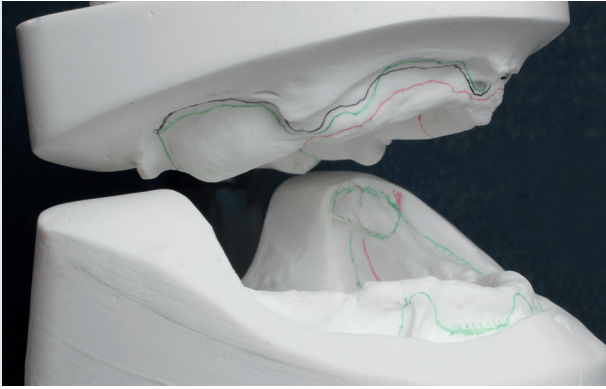

Fig. 4: Articulated models: Angle Class III malocclusion is clearly visible.



Fig. 5: Customized impression tray and registration device form a unit.

The Angle Class III malocclusion can be clearly seen on the articulated models (Fig. 4).

Individual impression-taking and recording of the maxillomandibular relation

High demands are also placed on custom trays, because the functional impression plays a pivotal role in achieving precisely fitting dentures. The objective is to maximize the supporting area of the denture base while taking into account the movements of the muscles. A suction effect must be established between the mucous membrane and denture base. For this purpose, the functional margins need to be fully contoured.

If flabby ridges are present, impressions of the gingiva should be taken using minimum pressure only.

The area of the flabby ridge was marked on the model and covered with a spacer to ease the pressure. Subsequently, customized trays were fabricated. To prevent the denture to shift upwards and forwards, a wide labial rim was created in the upper anterior vestibule. Dorsally, the tray ended at the vibrating line. The custom tray should also provide a suction effect in the mandibular jaw. Relatively voluminous margins were created to achieve this. Sufficient tongue space was provided and the anterior area was given a slightly concave contour.

The retromolar triangle was only thinly covered and, additionally, a concave buccal shield was created. A rim was placed on the crest of the alveolar ridge to provide a support surface for the placement of the Gnathometer M used for recording the jaw-to-jaw relation (intraoral needle point tracing). The bite rims of the Gnathometer M acted as the preliminary vertical dimension. An assembly of custom tray and registration device was used to take an impression of the oral situation (Virtual® Monophase) and to record the jaw-to-jaw relation (Fig. 5).

Set-up and try-in

Designed for classic occlusal schemes, the SR Phonares® II moulds are ideally suited for complete dentures. The facial meter (alameter) integrated into the SR Phonares II FormSelector assisted in selecting the moulds that were best suited for our patient. The teeth were set up in line with the set-up criteria for the classic occlusion. To prevent the flabby ridge from allowing the denture to move, the upper premolars were positioned close to the centre of the alveolar ridge (Fig. 6). We decided to place premolars in the dorsal area of the mandibular arch to achieve an external seal with the buccal mucous membrane and the lingual wall at closed mouth position (Fig. 7). The requirements of function and stability and patient specific characteristics were considered in the tooth set-up. The patient was in the habit of chewing food with her anterior teeth because of her Angle Class III malocclusion. This should be avoided in the new dentures by providing enough freeway space between the anterior upper and lower teeth at the set-up. A great deal of attention was

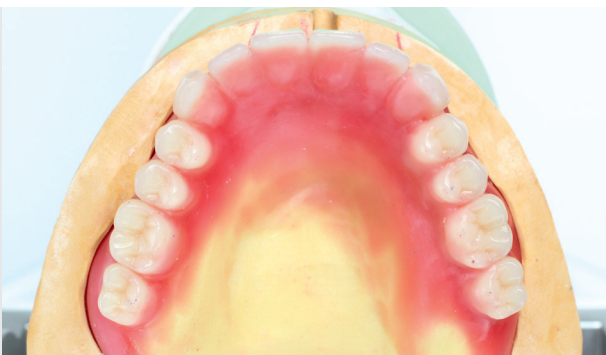

Fig. 6: Setting up the maxilla: the premolars are positioned closely to the alveolar crest.

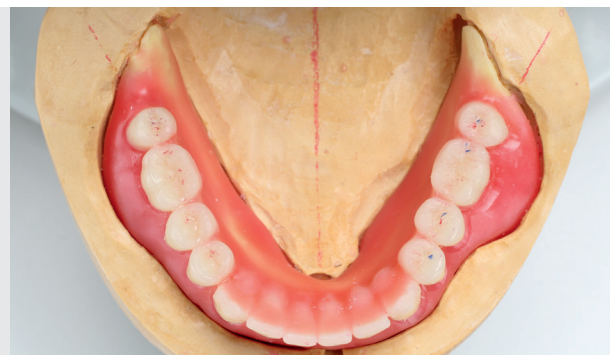

Fig. 7: Setting up the mandible: premolars are also used in the dorsal area.

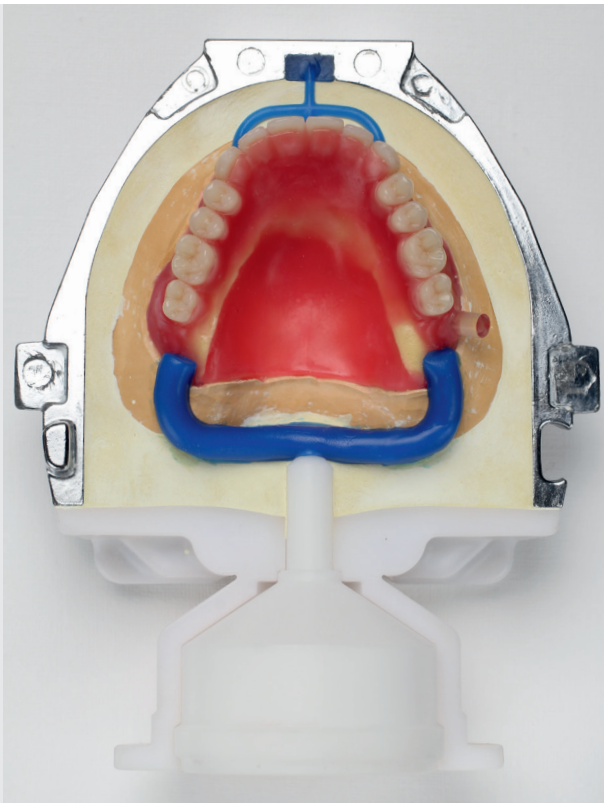


Fig. 8: Converting the wax-up to PMMA material (IvoBase system)

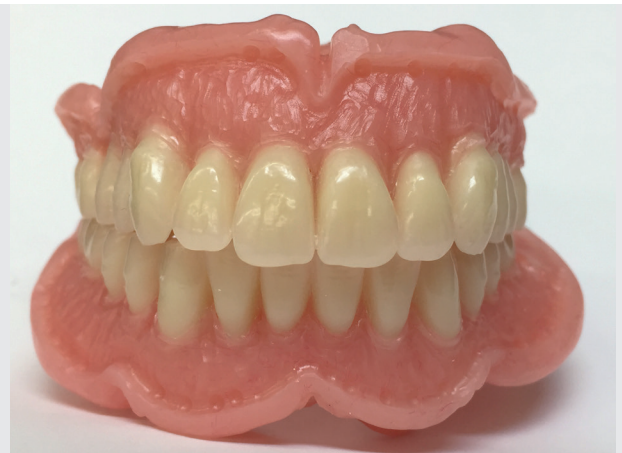

Fig. 9: Dentures prior to soft tissue customization

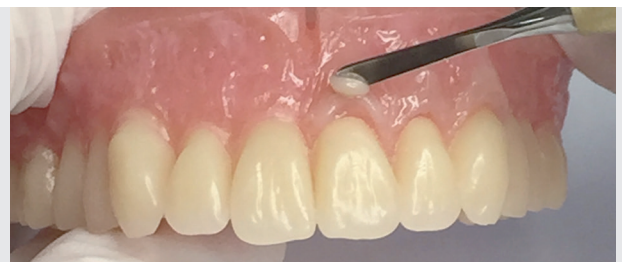

Fig. 10: The interplay of different shades of lab composite (SR Nexco) results in a three-dimensional depth effect. Morphological aspects are also considered in the customization of the soft tissues.

given to faithfully mimicking the natural oral soft tissues, as we wanted to provide a maximum level of esthetics already at the try-in stage. Five different shades of wax were used for characterization. By creating vestibular gingival portions that have a delicate yet effective appearance, the customized look can be accentuated. Esthetics, phonetics, occlusal vertical dimension and centric relation were assessed at the try-in of the wax-up and rated as good.

Completion

The wax-up was converted to resin using a proven method. We focused particularly on creating natural looking soft tissues to enable the dentures to integrate unobtrusively into

the oral surroundings. Accurately designed as they were, the dentures and prosthetic gingiva were converted to a PMMA resin (IvoBase High Impact) using the Ivobase® system. As polymerization shrinkage was fully compensated, 1 to 1 replications of the wax-ups were attained.

The denture wax-ups were flaked and sprued (Fig. 8). Once the moulds were created and the wax was boiled out, the flasks and teeth were prepared for the injection moulding process. The predosed denture base material was mixed and the capsules containing the mixed material and the flask were mounted on the injection device (Ivobase Injector). Once an appropriate program was selected, the injection process

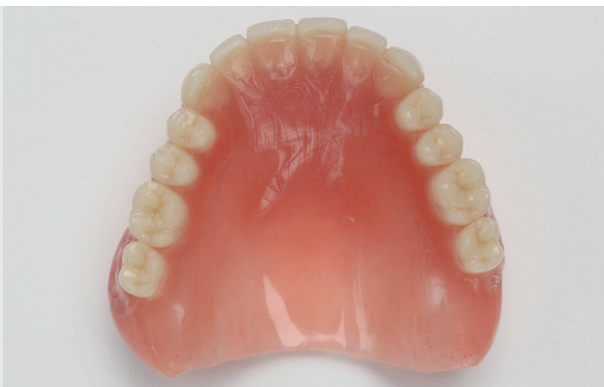

Fig. 11: Completed maxillary denture

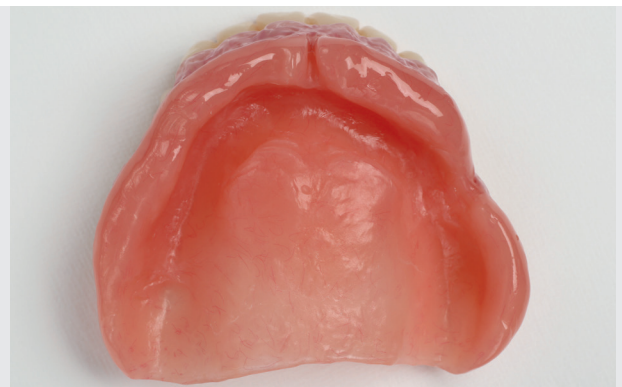

Fig. 12: View from the reverse side: the broad functional margin in the labial vestibule prevents the denture from shifting.

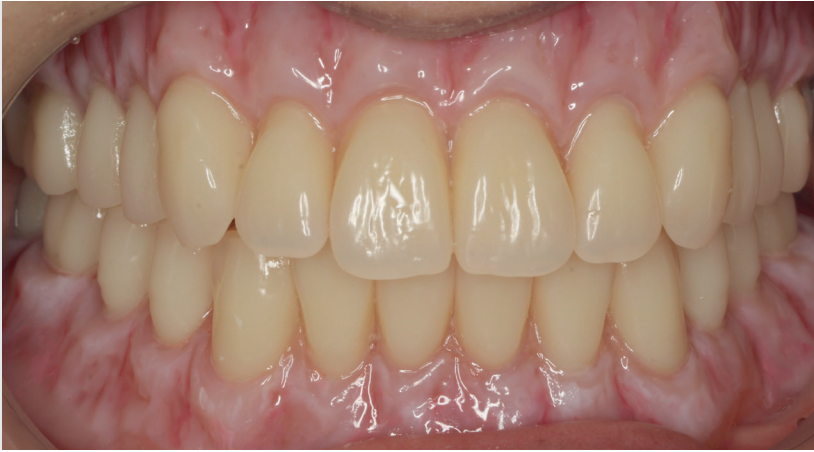

Fig. 13: Customized denture in situ: It's hardly noticeable that the patient is wearing conventional full dentures.



Fig. 14: Compared with the initial situation, the patient looks clearly younger and happier.

started. The result after divesting matched the requirements. Even fine details of the wax-up were exactly reproduced (Fig. 9). The dentures fitted the models accurately and required only minimal reworking.

Customized soft tissue reconstruction using SR Nexco

The three-dimensional soft tissue contours should be customized with shade characterizations. In the same way as different shades of wax are used for the try-in, different shades of resin should be used to reproduce the colour variations found in the natural gingiva. The light-curing lab composite SR Nexco® Paste is ideally suited for this purpose. This material is available in a comprehensive range of Gingiva shades including intensive shade variants. Natural-looking soft-tissue esthetics can be reproduced using a straightforward method. Given its non-sticky consistency, the composite is easy to apply and does not need to be warmed up prior to application. The lab composite offers a “vast playground” for individualized soft tissue creations as it is available in a broad spectrum of SR Nexco Stains and SR Nexco Paste Effect materials. Variations in the degree of soft tissue thickness, blood vessel density and pigmentation can be easily replicated to resemble the characteristics of the natural gingiva. The veneering material is optimally coordinated with the Ivobase denture base material.

We began by applying SR Nexco Paste Basic Gingiva BG34 extensively onto the denture base. A natural depth effect was produced with intensive SR Nexco shades, i.e. SR Nexco Paste Intensive Gingiva. Papillae and alveolar spaces were faithfully replicated using these materials. Next, the lighter and more transparent SR Nexco Paste Transpa was applied to enhance the optical colour depth effect. This method resulted in a natural looking appearance. The interplay of different shades, convex and concave surfaces in the alveolar area and subtle stipplings allowed us to achieve a three-dimensional depth effect quickly and easily (Fig. 10). The individual layers were light cured for 20 seconds each. Intermediate curing can, for instance, be performed with a Quick curing light. Prior to final polymerization in a light furnace, e.g. Lumamat 100, a glycerine gel (SR Gel) was applied onto the denture base in a covering but not too thick a coating to minimize the formation

of an inhibition layer. Only minor shape corrections were necessary before polishing the dentures. Tungsten carbide burs are best used for this step – the inhibition layer should be removed from the entire surface. Finishing was achieved by first smoothing the surfaces with rubber polishers, followed by mechanical high-gloss polishing at low rotational speed using a goat’s hair brush, leather buff and Universal Polishing Paste (Figs 11 and 12).

Result

The patient attained a “new” esthetic appearance due to the natural esthetics of the upper and lower dentures. Her smile told us that she got her self-confidence back, which was the most beautiful reward for our work. The dentures were characterized by a dynamic interplay of shades and natural light reflections, nuanced gingiva surfaces and healthy strong teeth (Fig. 13). They showed a stable fit and provided the desired suction effect. A phonetic and functional assessment of the criteria confirmed the success of the treatment. Compared to the preoperative situation, the new dentures imparted a clearly more youthful appearance to the face of the patient (Fig. 14).



Contact details:

Dr Jiro Abe
Abe Dental Office
1-12-43-2F Sengawa-cho, Chofu-shi
Tokyo
Japan
abedent@kch.biglobe.ne.jp



Kyoko Kokubo
ACE Dental Laboratory
3-32-11 Kyuden, Setagaya-ku
Tokyo 157-0064
Japan
ace-kokubo@m7.dion.ne.jp